

AL 977492

This material may be protected by copyright law (Title 17 U.S. Code)



comas that radiation. increased following surgery period. Nonsarcomas, and sarcomas at sites of either this as not been prospective. It should include of primary tumors, as well as, to control chromosomal abnormalities and to prevent mutant neoplasms. It is difficult to discern if same pleio-

# Blepharoplasty

## Avoiding Plastic Eyelids

E. Gaylon McCollough, MD, FACS, Jim L. English, MD

in part by the Division of Surgery, Stan-

deletion of chromosomal abnormalities 1984;

allie BL, et al: A shared recessive trait. *Sci USA*

General Aspects Springfield, Ill, 1978. Cites twice. NY

The goal of a facial plastic surgeon should be to correct the undesirable conditions for which he has been consulted and to avoid leaving his mark on the patient. By embracing the concept that prevention is better than cure, it is generally possible to avoid the "operated-on look" following cosmetic surgery. We describe a number of safeguards we use to preserve natural-looking eyes following lower lid blepharoplasty in men and women. The most common, permanent complication described following conventional lower lid blepharoplasty is the "wind eye." The condition is readily identified by an increase in scleral show between the limbus and lower lash margin. Closer evaluation will reveal inferomedial displacement of the lateral commissure, increased slope of the lateral third of each eyelid, a flattened, unanastomosed, pretarsal component, and an unnatural infralash crease produced by the healed incisional scar. These findings are one step short of ectropion; therefore, the methods herein described should help reduce the incidence of this more dreaded and serious complication of blepharoplasty.

(*Arch Otolaryngol Head Neck Surg* 1988;114:645-648)

A round eye is thought to occur following iatrogenic disruption or weakening of the tarsofascial sling or hammock. A more flaccid "hammock" is unable to resist the inferior and medial pull placed on the lower lid margin by postoperative contracture of the surgically created lower lid flap. Lower lid abnormalities may also occur in the unoperated-on lid as the lateral canthal tendon weakens and becomes more flaccid with age. Regardless of the cause, increased scleral show is generally accompanied by widening of the palpebral fissure and a more obtuse lateral canthal angle.

Many of the aforementioned unnatural postoperative sequelae may be avoided by lowering the conventional lower lid incision to a skin crease approximately 4 mm below the free border of the eyelid. This distance usually corresponds to the inferior border of the tarsus. As a direct result of a lowered incision, the pretarsal area is undisturbed. The retained integrity of the skin-orbicularis-tarsal-canthal tendon complex (ham-

mock) is maintained and can better resist the inferomedial pull of any contracting scar and/or excess skin removal.

### SKIN FLAP VS SKIN-MUSCLE FLAP

The two principal approaches to removing excessive tissues in the lower lid are the skin flap and the skin-muscle flap. The diagnosis of the problem determines which technique is used in a given patient.

Significant redundancy of lower lid skin is best corrected with a skin flap (Fig 1).

When a skin-flap technique is used, it is felt by some that downward traction on the lower lid during healing may be aggravated by a sheet of contracting scar under the previously undermined flap on the more mobile lower lid margin.

The "classic" lower lid skin incision, described by Castanares<sup>1</sup> and Rees,<sup>2</sup> is made approximately 1 to 2 mm below the free border of the lower lid (Fig 2). An incision this close to the lashes, however, could result in unnecessary disruption of the tarsofascial hammock, particularly if, when exposing lower lid fat, the surgeon removes any pretarsal orbicularis oculi muscle and/or disrupts the integrity of the orbital septum close to its insertion on the inferior border of the cartilaginous tarsal plate (Fig 3).

Accepted for publication Feb 26, 1988.  
From the Division of Otolaryngology, University of Alabama, Birmingham (Dr McCollough), and the Department of Otolaryngology, University of Arkansas Medical School, Little Rock (Dr English).  
Reprint requests to McCollough International Facial-Plastic Surgeons, 1516 S 20th St, Birmingham, AL 35205 (Dr McCollough).

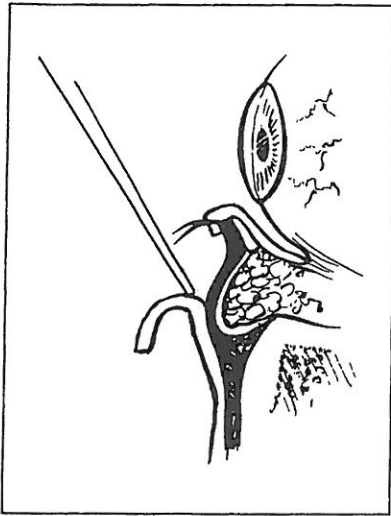


Fig 1.—Skin flap technique.

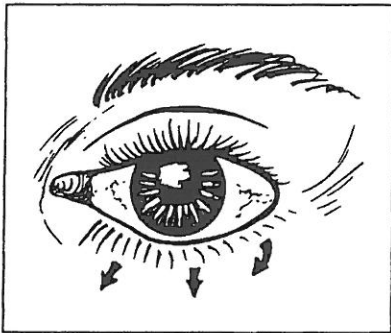


Fig 4.—Round eye. Note lateral canthal angle widening and increased scleral show. Arrows indicate downward retraction of eyelid due to loss of hammock strength. This can be avoided by preserving tarsofascial sling.

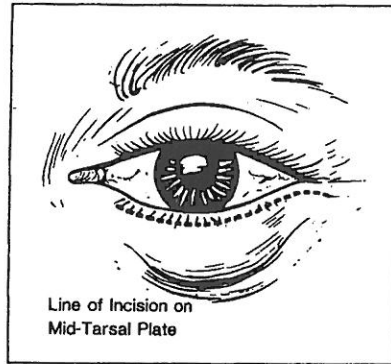


Fig 2.—“Classic” incision 2 mm below lower lash margin.

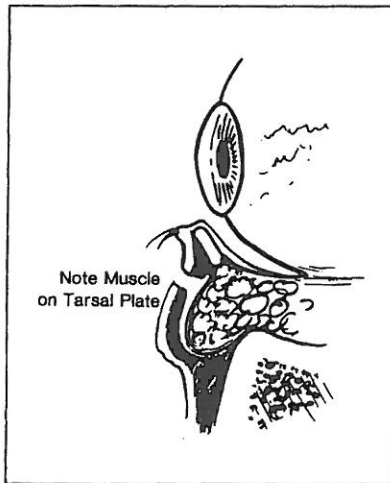


Fig 5.—Making incision 4 to 6 mm below the free margin of lid margin leaves orbicularis oculi muscle attached to the tarsus providing a strong functional “hammock.”

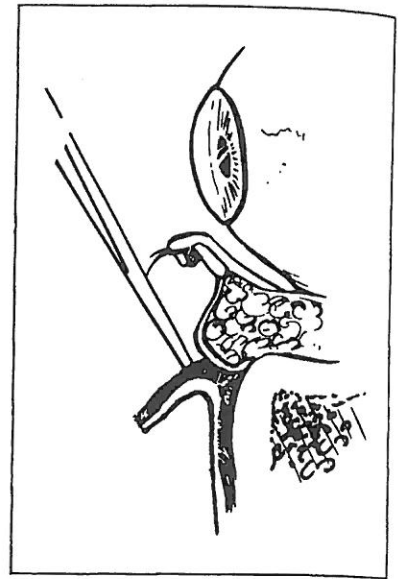


Fig 3.—Skin-muscle technique. Note paucity of remaining muscle left on tarsal plate.

excision of tissue superior and lateral to the canthus would suspend the lower lid flap to the lateral orbital soft tissue when the wound was closed and would tend to offset any inferomedial pull during healing. Later, he advocated suture plication of an iatrogenically weakened or senescent lateral canthal tendon in an effort to reduce the incidence of postoperative ectropion and/or rounding.

We have attempted to avoid the unwanted sequelae of blepharoplasty. Placing the skin incision farther inferiorly from the lid margin seems to be a key factor in avoiding surgical-appearing eyes.

Depending on the pattern of rhytids in the lower lid, the incision is made approximately 4 mm below the lower lash margin. By design, this leaves behind more of the overlying orbicularis oculi muscle fibers attached to the anterior border of the tarsal plate. Placing the incision through the orbicularis oculi muscle and orbital septum farther from the lid margin leaves more of the septal fibers attached to the inferior border of the tarsus, and better preserves the lower lid hammock connecting the medial and lateral canthal tendons (Fig 5). With more undisturbed tissue between the initial incision and the free margin of the eyelid, the amount and

Despite the amount of skin excised, any contraction of the lower lid flap during healing could produce an unwanted inferior and medial pull on the lid margin postoperatively. These combined vectors often produce blunting of the lateral commissure, an undesired increase in the amount of scleral show, and leave the patient with a more operated-on or unnatural-looking eye (Fig 4). If the pretarsal orbicularis muscle is removed, the pretarsal portion of the lid may be left with an abnormally flattened appearance.

The aforementioned undesirable sequelae can generally be eliminated by placing the lower lid incision along a line corresponding to the inferior border of the tarsus.

Contraction of the sheet of scar, which is thought to occur throughout any undermined area, is not as likely to occur with a skin-muscle flap technique. Still, it remains a factor that the surgeon must consider in planning his operation. We contend that avoiding disruption of the pretarsal hammock composed of skin, orbicularis oculi, the cartilaginous tarsus, and the most superior portion of the horizontal fibers of the orbital septum will tend to resist these contracting forces, providing skin (and/or muscle) removal is not excessive.

Webster<sup>3,4</sup> addressed the problem of inferior displacement of the lid margin via a flap suspension technique and lateral canthopexy. He felt that

dynam  
ring  
ished  
skin (t  
tial in  
is int  
geon  
durin  
skin s  
may s  
and r  
placec

PRE

Ess  
is the  
ing tl  
oppo  
and lo  
herald  
tively.  
sclera  
pointe  
graphi  
erativ

The  
ascert  
pulling  
and re  
good  
positiv  
floats  
positio  
al sur  
avoid  
a patie  
lower  
pentag  
section  
limbus  
ster<sup>3,4</sup>

tendon  
treatm  
Duri  
geon e  
lations  
woke  
pathok  
elicited  
aphtha  
le obts  
Duri:  
eyelid-  
certa  
tion to  
As a  
nds t  
ut doe



dynamic effect of postoperative scarring in the eyelid should be diminished. Furthermore, by leaving more skin (and muscle) superior to the initial incision, an additional safeguard is introduced. If, by chance, the surgeon should remove too much skin during the procedure, the undisturbed skin superior to the original incision may stretch with the passage of time and relieve some downward traction placed on the lower lid.

### PREOPERATIVE CONSULTATION

Essential to any cosmetic procedure is the preoperative consultation. During that time the surgeon has an opportunity to examine the patient and look for those conditions that may herald a potential problem postoperatively. The amount of preoperative scleral show, if present, is noted and pointed out to the patient. Photographic documentation of the preoperative state is essential.

The tonicity of the lower lid can be ascertained by the "snap test," i.e., pulling the lid away from the globe and releasing it quickly. A lid with a good "hammock" will snap back into position. On the other hand, a lid that floats back or remains in an abnormal position will usually require additional surgical maneuvers in order to avoid round eye and/or ectropion. (If a patient tends to have a rather lax lower lid, the surgeon may consider a pentagonal full-thickness wedge resection of the lower lid lateral to the limbus at the time of surgery. Webster<sup>3,4</sup> has advocated lateral canthal tendon plication as an alternative treatment for hammock flaccidity.)

During the consultation, the surgeon explains to the patient the limitations of surgery and attempts to evoke the patient's expectations. If pathologic conditions of the eyes are elicited or suspected, a preoperative ophthalmologic consultation should be obtained.

During the initial visit the patient's eyelid-brow complex is analyzed to ascertain if adjunctive surgical correction might be indicated (in addition to a blepharoplasty).

As a rule of thumb, blepharoplasty tends to improve the sags and bulges, but does not appreciably remove fine

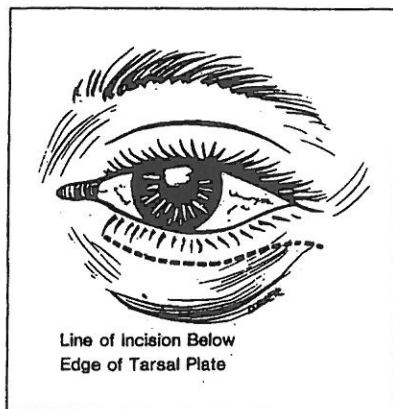


Fig 6.—Incision 4 to 6 mm below lower lash margin.

rhytids around the eye. If wrinkling is present, a discussion of a postoperative chemical peel for correction of this condition eight to 12 weeks following blepharoplasty should be a part of the preoperative consultation.

### OPERATIVE PROCEDURE

With the patient lightly sedated and in a reclined position at about 45°, the intended blepharoplasty skin incisions are outlined with a skin marking pen prior to injection of the local anesthetic. The proposed incision is planned for a skin crease approximately 4 mm below the free border of the lash margin. The incision begins a few millimeters lateral to the punctum medially and courses laterally just past a vertical line dropped from the lateral commissure (Fig 6). At this point, the incision curves inferiorly and laterally into a naturally occurring relaxed skin tension line in order to obtain a more aesthetically pleasing scar.

Each lid is then infiltrated with 1% lidocaine (Xylocaine) with 1:100,000 epinephrine for both hemostatic and anesthetic purposes.

If it is to be done in conjunction with a lower lid, the upper lid is corrected first. After the excessive upper lid skin has been removed and the fat pads have been adequately excised, one or two tacking sutures are placed to close the lateral aspect of the upper lid wound.

The previously outlined lower lid skin incision is made with a No. 15

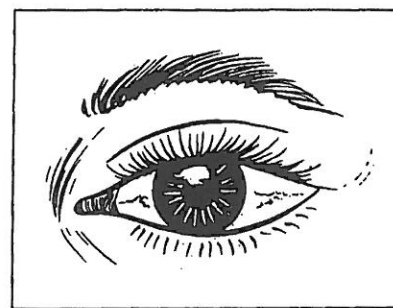


Fig 7.—When lower lid "hammock" is uninterrupted the natural shape of the eye is preserved in postoperative period. In thin lower lid skin the scars are virtually imperceptible.

blade, while a surgical assistance offers countertraction medially, inferiorly, and superiorly. The operating surgeon's hand places countertraction laterally so that the skin incision can be made quickly and precisely. This initial incision is made *only* through the skin.

A small curved iris scissor is used to spread and penetrate the orbicularis oculi muscle laterally. A more blunted scissor is then used to undermine the entire skin muscle flap.

While freeing the orbicularis oculi muscle from the orbital septum, it is wise not to disturb the periosteum overlying the infraorbital rim. Disruption of the periosteum could allow the orbicularis muscle to heal directly to the bone or frayed periosteum during the postoperative period. If this should occur, undue downward traction on the lower lid might produce lid distortions.

Once the undersurface of the orbicularis oculi muscle has been freed from the orbital septum, one blade of the scissor is placed in the previously created pocket beneath the muscle. The other blade of the scissor is placed externally along the initial skin incision. The incision through the orbicularis oculi muscle and subcutaneous tissue is completed when the blades of the scissors are approximated on a 45° bias through the full thickness of the flap exiting at the previously made skin incision.

Since the skin-muscle flap is selected in those patients with minimal skin redundancy, the flap is reflected primarily to remove excessive fat (Fig 5). The fat pads can be more accurately

ly identified by making a "nick" in the orbital septum while placing a small amount of digital pressure on the globe. This maneuver causes the excessive fat to bulge through the orbital septum for easy amputation. Prior to excision, the base of the fat stalk is injected with local anesthetic and generously cauterized with bipolar cautery before its removal. Only the portions of fat that exude easily through the defect in the orbital septum are removed.

After each fat "compartment" has been adequately treated, the skin-muscle flap is draped superiorly and laterally. Small vertical cuts are made into the overlapping portions of the skin-muscle flap, dividing the tissue to be removed into three or four segments. This maneuver adds a measure of safety and tends to prevent excess skin removal.

We have discovered that when both the skin and muscle incisions are placed inferior to the tarsus, it is not necessary to remove a strip of muscle

from the undersurface of the skin-muscle flap. Once the overlapping skin and muscle have been removed, the wound edges are precisely closed with a 6-0 catgut suture.

In patients with festoons of lower lid skin in which a skin-flap technique is used, the orbicularis oculi muscle is divided with a separate incision 3 or 4 mm inferior to the initial skin incision. The margins of the orbicularis oculi muscle are reapproximated with interrupted 6-0 chromic catgut sutures after fat removal.

When either skin flaps or skin-muscle flaps are selected, the lower incision leaves behind more innervated orbicularis oculi muscle on the anterior aspect of the tarsal plate. In addition, fewer muscle fibers are disturbed laterally, thereby preserving the circumferential contracting mechanism of the orbicularis oculi superior to the blepharoplasty incision.

The surgical scar resulting from the more inferiorly placed incision heals quite nicely, just like the conventional

higher placed incision, and is generally quite acceptable (Fig 6).

We believe that prevention is better than cure. If the safeguards herein described are embraced, the incidence of postoperative displacement of the lid margin can be significantly reduced (Fig 7) and, in most cases, ectropion or an unsightly round eye can be avoided.

#### COMMENT

Rounding of the eye can be a common postoperative sequelae of blepharoplasty. In our experience, relocating the conventional lower lid incision to a more physiologic position has proven beneficial. Leaving the pretarsal soft tissues and the associated "hammock" undisturbed may avoid the "operated-on" or surgical-appearing eye. The scar from the more inferiorly placed lower lid incision is aesthetically acceptable, and, in most cases, can be camouflaged with makeup one week following surgery.

#### References

1. Castanares S: Blepharoplasty for herniated intraorbital fat: Anatomical basis for a new approach. *Plast Reconstr Surg* 1951;8:46-58.
2. Rees TD: Surgical procedures, in *Aesthetic*

*Plastic Surgery*. Philadelphia, WB Saunders Co, 1980, pp 470-524.

3. Webster RC: A flap suspension technique in blepharoplasty on lower lids. *J Dermatol Surg*

*Oncol* 1978;4:159.

4. Webster RC: Suspending sutures in blepharoplasty. *Arch Otolaryngol Head Neck Surg* 1979;105:601-604.

THIS COPY IS NOW AVAILABLE FOR A FIVE-  
YEAR PERIOD. IT MAY NOT BE REPRODUCED  
OR TRANSMITTED IN ANY FORM OR BY ANY  
MEANS, ELECTRONIC OR MECHANICAL, FOR  
PROFIT OR NON-PROFIT, WITHOUT THE  
WRITTEN PERMISSION OF THE PUBLISHERS.  
FOR A REPORT ON REPRODUCTION RIGHTS  
CONTACT THE COPYRIGHT CLEARING CENTER  
AT 222 ROSS STREET, WESTPORT, MA 01886  
OR CALL (617) 870-8700.

INTERLIBRARY LOAN  
MELVILLE LIBRARY  
AHECPINE BLUFF

MELVILLE LIBRARY  
AHECPINE BLUFF

Eff

Sto

Takesh  
Yasuya

• Ei  
and st  
were c  
testing  
live fr  
more  
rate w  
assign  
and 3  
assign  
former  
better  
(Arc  
1988;1

I dior  
he  
a co  
unkno  
abnor  
is a  
circul  
propo  
Howe  
clude  
consic  
cases  
loss, &  
ments  
origin  
hance  
know  
ness.<sup>4</sup>  
the d  
due to  
hemaj  
tion,<sup>5</sup>  
blood  
reatr  
We  
(DF)

Accep  
From  
Medicir  
Shoku  
Drs Kt  
School  
Jagoya  
Drs Y.  
Shivers  
Jemun  
Repr.  
ology,  
Akush

ch C