

## CASE REPORT

# Fat Augmentation of the Anterior Vaginal Wall: A Novel Use of Fat Augmentation in Enhancing the Female Sexual Experience

Lionel D. Meadows, MD, FACOG; Yaniris R. Avellanet, MD; Jim English, MD

*This is a case series of 2 female patients with long-standing histories of decreased sexual function and pelvic organ prolapse who underwent augmentation of the anterior vaginal wall using autologous fat grafting, in conjunction with other cosmetic procedures. Fat augmentation of the anterior vaginal wall with its enhanced permanence could be a safe and long-lasting alternative to improve female sexual function in this group.*

Fat transfer was first documented in 1893 by German physician Franz Neuber<sup>1</sup> and was popularized in the 1980s by American plastic surgeon Sydney Coleman, whose fat grafting techniques are used by many cosmetic surgeons today.<sup>2</sup> Harvested adipose tissue has long been used as a natural injectable filler to augment the face and many areas of the body for physiologic purposes, reconstructive treatments, and cosmetic enhancements.<sup>3,4</sup> The clinical longevity of the graft is highly variable, and the volume of large grafts decreases significantly over time.<sup>3,4</sup> The presumed mechanism of tissue loss appears to be primarily insufficient vascularity and cell death.<sup>3,4</sup> This concept has led to the approach of decreasing the size of fat grafts, as suggested by Coleman, with the hope that a smaller graft will mean that more fat is adjacent to viable recipient tissue, resulting in improved availability and diffusion of cellular nutrition until neovascularization occurs.<sup>4</sup> Coleman described an appropriate technique of harvesting, transport, and implantation of fat with small-lumen cannulas and syringes to protect the fat from mechanical damage, maintain its tissue architecture, and encourage long-term survival and reliable results.<sup>2</sup>

Implementation of this technique has led to improved fat grafting outcomes for many surgeons.

Vaginal childbirth is the primary cause of pelvic organ prolapse, causing stretching, dislocation, tearing, and avulsion of pelvic tissues.<sup>5,6</sup> Aging and chronic conditions such as constipation, which put excess strain on supporting pelvic structures as the result of increased intra-abdominal pressure, can also have an effect on the pelvic organs and can negatively affect a woman's sexual experience.<sup>5</sup> Female sexual dysfunction, characterized as low libido, problems with sexual arousal, inability to achieve orgasm, and dyspareunia, is a multicausal and multidimensional problem combining sexual, physiologic, physical, psychological, and interpersonal determinants with high prevalence in women (43%).<sup>7-10</sup> Studies have shown that pelvic floor symptoms are significantly associated with reduced sexual arousal, infrequent orgasm, and dyspareunia.<sup>11</sup>

The close physical proximity of the urethra and the clitoris to the anterior vaginal wall suggests an association between these anatomic structures and sexual function.<sup>12</sup> The term *clitoris-urethrovaginal complex* has been used to refer to the most commonly known term, the *Gräfenberg* or *G-spot*.<sup>13-15</sup> The G-spot is a term used to describe the area of the vagina that contains an erogenous zone that when stimulated can produce high levels of sexual arousal and powerful orgasms. The G-spot is usually said to be located about 1 to 3 inches inside the vagina, over the urethra, on the anterior wall. Studies have shown that some women need direct, external, clitoral stimulation, whereas others may reach orgasm by penetration and thrusting that directly stimulate the internal clitoris and vaginal wall structures and indirectly the external part of the same organ.<sup>16</sup>

Fat augmentation of the anterior vaginal wall, including the area said to contain the G-spot, may be considered

Received for publication December 28, 2010.

From the English Plastic and Cosmetic Surgery Center, Little Rock, Ark.  
Corresponding author: Lionel D. Meadows, MD, FACOG, Meadows Surgical Arts, 30931 Hwy 441 S, Commerce, GA 30529-6655 (e-mail: meadowsmid@gmail.com).

as a means of enhancing a woman's sexual experience in those with a history of sexual dysfunction and pelvic floor disorders. Synthetic fillers have been used to increase the volume of the area said to contain the G-spot to increase sexual satisfaction. Filler applied to this area is marketed as "the G-shot." Unfortunately, no literature is available to support the success of this procedure. Fillers are also successfully used to improve sexual function in men. Glans penis augmentation with injectable hyaluronic acid gel has been reported to have long-term efficacy of 1 year after injection and high satisfaction rates without serious adverse reactions.<sup>17</sup> Collagen-like fillers are used to treat stress urinary incontinence, but are easily absorbed by the body and have to be reapplied to maintain improvement.<sup>18</sup> Although safe and successful, these fillers are absorbed quickly, usually within 6 months. Because reapplication is costly, a more long-term approach is needed. When techniques proven to improve fat graft retention are used, fat augmentation in theory should last longer than synthetic fillers. Fat augmentation of the anterior vaginal wall with its enhanced permanence could be a safe and long-lasting alternative to improve female sexual function in this group.

### Case Series

#### Case #1

This is the case of a 51-year-old female who presented for cosmetic evaluation requesting facial and abdominal enhancement and a gynecologic evaluation. The patient has a medical history significant for type 1 diabetes, adequately controlled with an insulin pump, and a long-standing history of diminished ability to achieve orgasm. On examination, the patient was noted to have a grade II rectocele, as well as facial aging. Potential cosmetic and gynecologic procedures were discussed, including the benefits of fat augmentation of the anterior vaginal wall for potential improvement of sexual satisfaction. The patient underwent rectocele repair with fat augmentation of the anterior vaginal wall and several facial cosmetic procedures. A total of 20 cm<sup>3</sup> of fat was harvested and 3.5 cm<sup>3</sup> of fat was transferred to the anterior vaginal wall, mostly to the G-spot area. The additional procedures were successfully completed. The total procedure time was 3 hours and 11 minutes. The patient was seen on postoperative day 1 and reported no pain at the graft site. She was seen weekly through her first 6 weeks and resumed intercourse at postoperative week 5. The patient reported sexual satisfaction with orgasm on attempt at vaginal intercourse, although pain upon

entry was present. At her 3-month follow-up and the Female Sexual Function Index (FSFI) survey at 14 months post surgery, the patient still reports improved sexual satisfaction with intercourse and achievement of orgasm at close to every attempt. No pain or discomfort with penetration was noted in her 14-month postoperative FSFI survey.

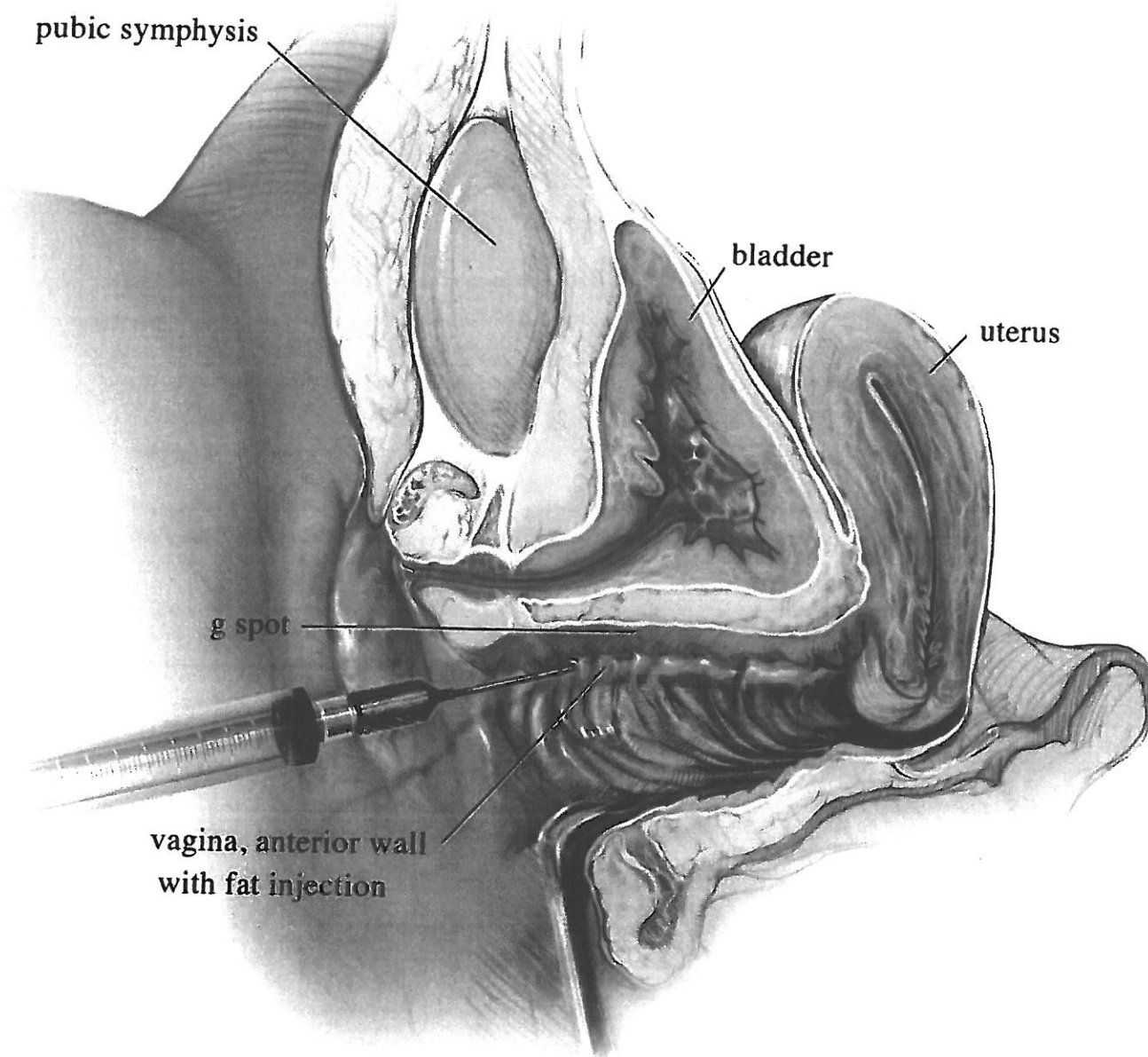
#### Case #2

This is the case of a 44-year-old female who presented for evaluation requesting vaginal and facial enhancement. The patient has a history of chronic constipation and 3 spontaneous vaginal deliveries, and a long-standing history of decreased sexual functioning with intercourse. On examination, the patient was found to have a grade I rectocele with a deficient perineum. Potential cosmetic and gynecologic procedures were discussed, including the benefits of fat augmentation of the anterior vaginal wall for potential improvement of sexual satisfaction. The patient was given various questionnaires to answer preoperatively, including the FSFI and the Sexual Quality of Life Questionnaire-Female (SQoL-F). The patient underwent rectocele repair, perineoplasty, and fat augmentation of the anterior vaginal wall and labia majora. A total of 24 cm<sup>3</sup> of fat was harvested, and 10 cm<sup>3</sup> was transferred to the anterior vaginal wall, mostly its central region; 5 cm<sup>3</sup> was transferred to each labia majora. The additional procedures were successfully completed. The total procedure time was 1 hour and 34 minutes. The patient was seen on postoperative week 1 and reported no pain at the graft site. The patient was instructed not to have intercourse for 6 weeks. The patient was seen on postoperative day 10 and reported no problems. She was seen again on postoperative week 5, still reporting no problems, and resumed intercourse at postoperative week 8. The patient reported desire and arousal for sexual activity with orgasm, although discomfort or pain with vaginal penetration was present upon entry and during intercourse. The 3-month postop survey indicates that the patient now achieves orgasm with almost every attempt.

### Operative Technique of Fat Harvesting and Transfer

A 2-mm punch was used to make an adit in the right lateral thigh in the first case and in the lower umbilical area in the second case for fat harvesting. A blunt-tip cannula attached to a 10-mL Luer-Lok syringe was inserted through the incision, and the plunger was pulled back gently to minimize negative





**Figure 1.** *Sagittal cut-away view of the pelvis.*

pressure. After harvesting of fat, the cannula was removed from the syringe and was replaced with a plug; the plunger was removed, and the fat centrifuged at 3000 rpm for 2½ minutes to separate the fat at upper, medial, and lower levels. Exposure of the fatty tissue to open air was avoided to prevent rapid fat

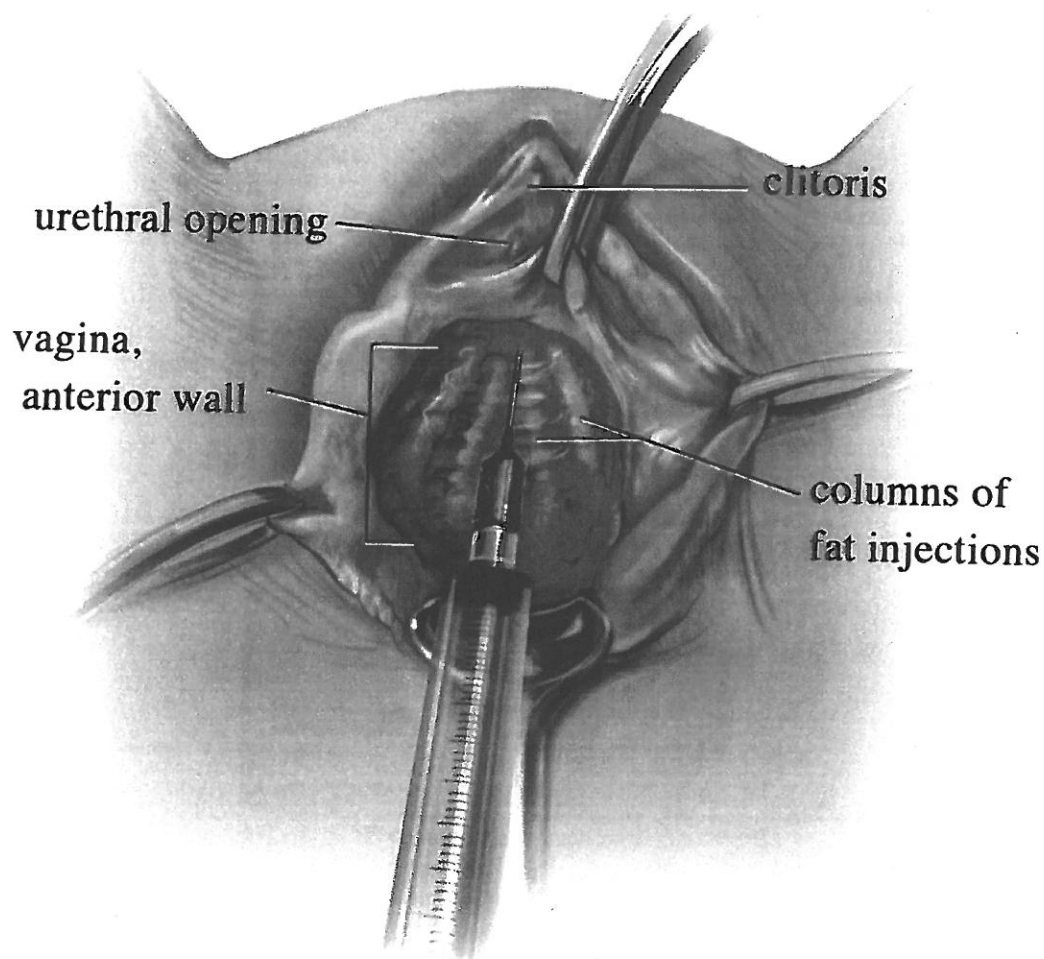
desiccation. The upper layer containing oil was decanted, and the lower layer containing blood, water, and lidocaine was discarded. The fat was transferred to a smaller 1-mL Luer-Lok syringe used for fat infiltration. The stab incision was left open to allow for drainage.

A dorsal lithotomy position was utilized for the vaginal procedures. The vesicovaginal space was developed using normal saline for hydrodissection. A 19-gauge blunt cannula was inserted through a small stab incision 2 cm inferior and posterior to the urethral orifice. The cannula was advanced to the anterior cul de sac and was slowly withdrawn while the plunger was pressed, creating a linear thread of fat grafting, as

seen in Figure 1. This technique was repeated in a fanning fashion, mostly along the central part of the anterior vaginal wall, as seen in Figure 2.

### Discussion

Volume loss is a recurrent theme with aging. The vagina and the vulva atrophy with increasing age with loss of skin elasticity decreased vaginal lubrication,



**Figure 2.** *Lithotomy view of the pelvis.*

increased irritation, and loss of subcutaneous fat in the labia majora.<sup>5,6</sup> Review of literature reveals no data on long-term fillers used in the vulvovaginal area to correct some of the effects caused by aging or to improve sexual functioning.

Fat augmentation of the anterior vaginal wall was successful and safe in both of these cases. This procedure was performed with multiple other cosmetic procedures and did not result in morbidity or complications. Potential complications would include infection, bladder perforation, and lack of effect resulting from poor fat survival or poor placement. Because vacuum pressure can destroy fat cells, implementing the "closed syringe technique" instead of traditional liposuction for fat retrieval could result in improved outcomes and more permanent results.<sup>19</sup> Also, maintenance of good health habits, such as smoking cessation, has been shown to increase fat cell survivability by decreasing wound healing complications in free-tissue transfer.<sup>20,21</sup> Certainly, a comparison trial with nonpermanent filler versus fat transfer would be ideal. Adipose tissue is an ideal filler that can be made readily available and, with proper care, handling, and patient compliance, can be permanent.

This case series presented some limitations, and future recommendations were considered. Sexual dysfunction and quality of life can be assessed objectively through the administration of questionnaires, such as the FSFI and the SQoL-F. These tools should become standard in the preoperative and postoperative evaluation of these patients to obtain an objective measure of sexual function before and after the procedures. Measuring the thickness of the vagina via ultrasound preoperatively could be another objective way of comparing surgical outcomes postoperatively. A thorough gynecologic and sexual evaluation should be included to assess whether menopause and use of hormone replacement therapy after this procedure have any additional effect on female sexual function. Case-control studies should be performed to assess the effects of fat transfer versus other pelvic procedures separately, as well as its effects on female sexual function.

The fat augmentation described here offers advantages over both current options for improving female sexual satisfaction. Fat offers a longer-lasting result than the collagen or hyaluronic fillers currently used for "the G-shot." In addition to the advantages of using fat as a natural filler, fat augmentation of the anterior vaginal wall does not present the risk of insertional dyspareunia frequently seen after the levator fascia plication of a traditional vaginal reconstruction. If future findings substantiate the fat augmentation of

the anterior vaginal wall procedure, it could be an alternative for those who wish to improve their sexual function without posterior colporrhaphy.

For the patient who desires improvement in sexual function and has a history of pelvic floor dysfunction, fat augmentation to the anterior vaginal wall with or without posterior repair can offer a safe and long-lasting solution.

### Acknowledgments

All illustrations are provided courtesy of Colby Polonsky. The authors would also like to acknowledge Casey Howard for review of literature and editorial work.

### References

1. Neuber F. Fettransplantation. *Chir Kongr Verhandl Dtsch Ges Chir.* 1893;22:66.
2. Coleman SR. *Structural Fat Grafting.* St Louis, Mo: Quality Medical Publishing; 2004:39–50.
3. Zhu M, Zhou Z, Chen Y, et al. Supplementation of fat grafts with adipose-derived regenerative cells improves long-term graft retention. *Ann Plast Surg.* 2010;64:222–228.
4. Moseley TA, Zhu M, Hedrick MH. Adipose-derived stem and progenitor cells as fillers in plastic and reconstructive surgery. *Plast Reconstr Surg.* 2006;118(suppl):121S.
5. Tinelli A, Malvasi A, Rahimi S, et al. Age-related pelvic floor modifications and prolapse risk factors in postmenopausal women. *Menopause.* 2010;17:204–212.
6. Farage M, Maibach H. Lifetime changes in the vulva and vagina. *Arch Gynecol Obstet.* 2006;273:195–202.
7. Basson R, Berman J, Burnett A, et al. Report of the International Consensus Development Conference on Female Sexual Dysfunction: definitions and classifications. *J Urol.* 2000;163:888–893.
8. Laumann EO, Paik A, Rosen RC. Sexual dysfunction in the United States: prevalence and predictors. *JAMA.* 1999;281:537–544.
9. Addis IB, Van Den Eeden SK, Wassel-Fyr CL, Vittinghoff E, Brown JS, Thom DH. Reproductive risk factors for incontinence study at Kaiser Study Group: sexual activity and function in middle-aged and older women. *Obstet Gynecol.* 2006;107:755–764.
10. Laumann EO, Gagnon JH, Michael RT, Michaels S. *The Social Organization of Sexuality: Sexual Practices in the United States.* Chicago, Ill: University of Chicago Press; 1994.

11. Handa VL, Harvey L, Cundiff GW, Siddique SA, Kjerulff KH. Sexual function among women with urinary incontinence and pelvic organ prolapse. *Am J Obstet Gynecol.* 2004;191:751–756.
12. O'Connell HE, Sanjeevan KV, Hutson JM. Anatomy of the clitoris. *J Urol.* 2005;174(4 Pt 1): 1189–1895.
13. Gravina GL, Brandetti F, Martini P, et al. Measurement of the thickness of the urethrovaginal space in women with or without vaginal orgasm. *J Sex Med.* 2008;5:610–618.
14. Foldes P, Buisson O. The clitoral complex: a dynamic sonographic study. *J Sex Med.* 2009;6: 1223–1231.
15. Gräfenberg E. The role of urethra in female orgasm. *Int J Sex.* 1950;3:145–148.
16. Gruenwald O, Lowenstein L, Gartman I, Vardi Y. Physiological changes in female genital sensation during sexual stimulation. *J Sex Med.* 2007;4:390–394.
17. Kim JJ, Kwak TI, Jeon BG, Cheon J, Moon DG. Human glans penis augmentation using injectable hyaluronic acid gel. *Int J Impot Res.* 2003;15:439–443.
18. Martins SB, Olivera E, Castro RA, et al. Clinical and urodynamic evaluation in women with stress urinary incontinence treated by periurethral collagen injection. *Int Braz J Urol.* 2007;33:695–703.
19. Shippert RD. Vacuum pressures during autologous fat transfer (AFT): a study of the closed syringe type and other aspirator pressures. *Am J Cosmetic Surg.* 2009;26:230–235.
20. Krueger JK, Rohrich RJ. Clearing the smoke: the scientific rationale for tobacco abstention with plastic surgery. *Plast Reconstr Surg.* 2001;108: 1063–1073.
21. Shiffman MA, Mirrafati S. Fat transfer techniques: the effect of harvest and transfer methods on adipocyte viability and review of the literature. *Dermatol Surg.* 2001;27:819–826.