

CLINICAL TECHNIQUE

Treating Internal Nasal Valve Collapse: The Intranasal Valvuloplasty

Troy E. Major III, DO; Jim L. English, MD, FACS, FICS

Introduction: Nasal obstruction requires a careful and thorough examination of the nose and nasal cavity. Particular interest should be placed on the internal and external nasal valves and their collapse. We discuss a simple yet effective technique to resolve obstruction of the internal nasal valve, called the intranasal valvuloplasty/valvulopexy. These procedures can be of benefit for valvular obstruction, especially postrhinoplasty.

Objective: Nasal obstruction as sequela to aesthetic surgery may occur more often than recognized. The purpose of this paper is to explain a relatively simple yet expedient technique to address nasal valvular collapse.

Method: Retrospective review of patients treated with the intranasal valvuloplasty/valvulopexy technique in the outpatient setting.

Results: We reviewed our last 6 patients with the technique our senior author has been performing for 20 years. The patients noted 80–100% subjective improvement and we noted comparable objective improvement. Of the 6 patients, 50% were done bilaterally and 33% were combined with either a septoplasty or with a septorhinoplasty. Of these, 66.7% had a history of prior nasal surgery, usually rhinoplasty.

Discussion: The valvuloplasty is an effective and straightforward approach to nasal valve collapse either alone or in conjunction with other rhinological procedures.

Introduction

Nasal obstruction requires a careful and thorough preoperative examination of the nose and nasal cavity. Particular interest should be placed on the internal and external nasal valves and their collapse. It is

paramount that if cosmetic surgery is performed on a nose it should be functional as well as aesthetic. One should not compromise the airway, creating a nasal cripple for an aesthetic outcome. Nasal septal deviation and hypertrophic turbinates are a common cause of obstruction and easy to evaluate; the nasal valves, however, require more diligence during examination. Numerous techniques have been devised for repair of valvular collapse,¹ from anchoring suspensions² to cartilage grafting^{1,3,7} and lateral crural “J” flaps,⁴ with varying degrees of success and operator expertise needed. We have devised a simple yet effective technique that addresses the collapse of the internal nasal valve, and it can easily be done alone or in conjunction with other nasal procedures.

The internal nasal valve consists of the attachment of the upper and lower lateral cartilages, the anterior portion of the inferior turbinate, and the attachment of the nasal septum to the lower lateral cartilages.⁵ It is located approximately 1.3 cm from the nares, with an average cross-sectional area of 0.73 cm,² and is normally the narrowest segment of the nasal airway.⁵ Anterior rhinoscopy should be performed to evaluate the nasal septum, the turbinates, the valves, and the mucosa (Figure 1). Further testing of the nasal valve using the Cottle maneuver and the modified Cottle maneuver helps to identify valvular collapse. This can be secondary to aging with collapse and descent of the redundant soft tissue envelope and/or iatrogenic disruption of the scroll with or without overresection of the lower lateral cartilage (Figures 2 and 3) and/or trauma, etc.

Several techniques have been used to treat this malady. We will describe these to demonstrate the simplicity of our technique. Suspension techniques use a bone anchor from the bony orbital rim area. A suture from the bone anchor is placed in the valvular cartilage followed by tightening of the suture.² The suture can often be palpated following this procedure. Spreader

Received for publication January 3, 2008.

From the American Academy of Cosmetic Surgery.

Corresponding author: Troy E. Major III, DO, Southeast Ent Consultants, 129 la Terra, Cape Girardeau, MO 63701 (e-mail: troymajor@charter.net).

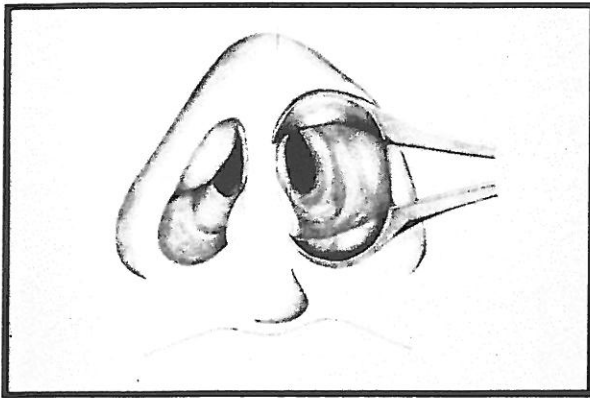


Figure 1. Using anterior rhinoscopy, valvular redundancy identified.

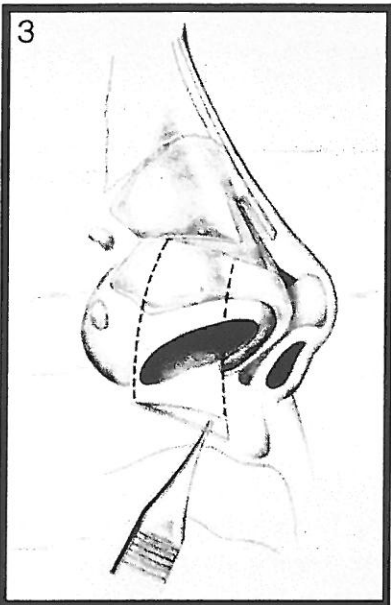
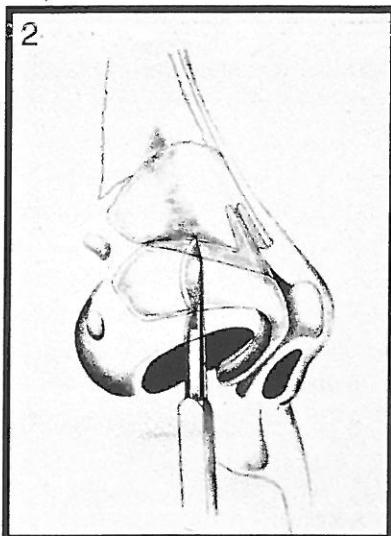


Figure 2. Iatrogenic damage to scroll area.

Figure 3. Overresection of cartilage leading to valvular collapse.

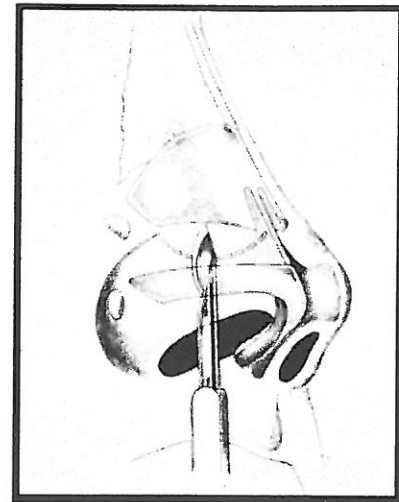


Figure 4. A curvilinear incision is created with a #15 blade starting at the posterior limit of the lower lateral cartilage, taking care not to approach the septum.

grafts work but require the use of graft material harvested from other locations, increasing time and possible donor site problems. Perceptible widening of the nose is also possible. Alar batten grafts work in the appropriate patient but again require graft material and can have some external contour changes that have to be considered.^{1,3} Flaring sutures may be used with or without spreader grafts but work best in conjunction with spreader grafts and require an open technique. Injectable fillers have recently been used, though long-term results are yet to be seen. The lateral crural "J" flap consists of redundant vestibular skin removal in the valvular area through an incision caudal to the lower lateral cartilage in a more lateral fashion.⁴ Lateral crus pull-up techniques involves freeing the lower lateral cartilage and suture fixation after drilling a hole in the bony pyramid for attachment.⁶

Technique

The patient is prepped and draped in the usual fashion with the nose initially packed with pontocaine and phenylephrine for 5–8 minutes, at which time the packing is removed. The incision site is injected conservatively with 2% lidocaine with 1:50 000 epinephrine to prevent distortion. Next, a curvilinear incision is created with a #15 blade starting at the posterior limit of the lower lateral cartilage to avoid an incision too deep within the nose to close. The incision should not approach the septum, so as to prevent cicatricial scar formation (Figure 4). It is most important to make certain that your incision is at the

lower lateral cartilage to provide support. A sub-mucosal pocket is then dissected using scissor technique and carried superiorly under the upper lateral cartilage in a supraperichondrial plane (Figure 5). The pocket should be widely undermined to allow the tissue to be advanced easily without distortion (Figure 6). The tissue is then advanced anteriorly, back cuts are made with excision of mucosal excess, and the incision is then closed with 5-0 chromic suture in an interrupted fashion taking care not to ensnare the surface outer skin or cartilage (Figure 7). The nose is then taped in the standard rhinoplasty fashion and a 4-0 plain gut suture on a short Keith needle is placed through the external tape, nasal skin, cartilage, internal valve across the incision internally, and back out, and then tied over the tape, effectively pexing the internal valve up and removing any dead space. Do not overtighten the sutures, as this could lead to skin necrosis with subsequent swelling (Figure 8A–C). On postoperative day 6, the patient is reevaluated and the pexy suture is cut and the taping removed. The nasal valve is then inspected by anterior rhinoscopy and should be patent with minimal edema (Figure 8D).

Results

Using the methods described on the last 6 patients treated and reviewing both on subjective and objective parameters, a retrospective review was performed. The subjective parameter used was nasal congestion and improvement noted at 1 week and 1 month. Final results were at 6 to 12 months. Objective improvement was anterior rhinoscopy of the internal valve. Six patients were treated with this technique, with an average age of 46.8 years and a male to female ratio of 1:2. Fifty percent of the procedures were done bilaterally and 33% were combined with either a septoplasty or with a septorhinoplasty. It was also noted that 66.7% of patients presented to us had a history of prior nasal surgery, usually rhinoplasty. Follow-up revealed that 80–100% noted subjective total improvement, and we noted significant objective improvement as well (Table 1).

Discussion

Valvular collapse can be a troublesome dilemma to both the rhinologic surgeon and the patient. There are a multitude of treatments for this with varying degrees of success and complexity. The intranasal valvuloplasty/valvulopexy we have shown is an effective and straightforward approach to nasal valve

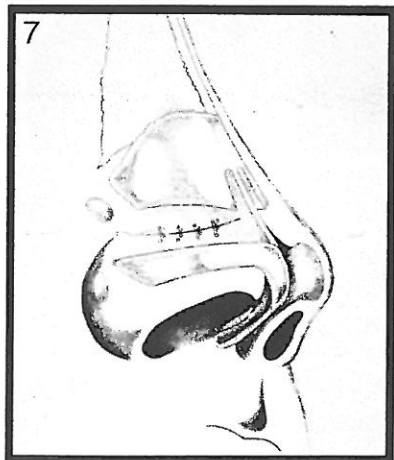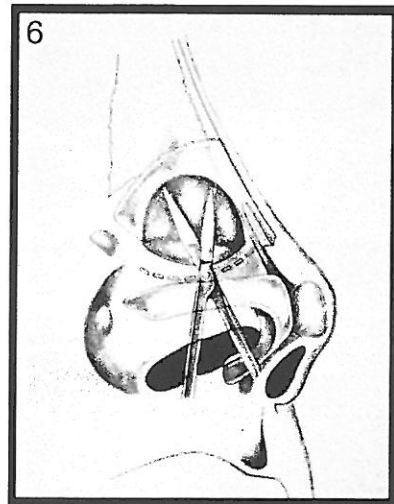
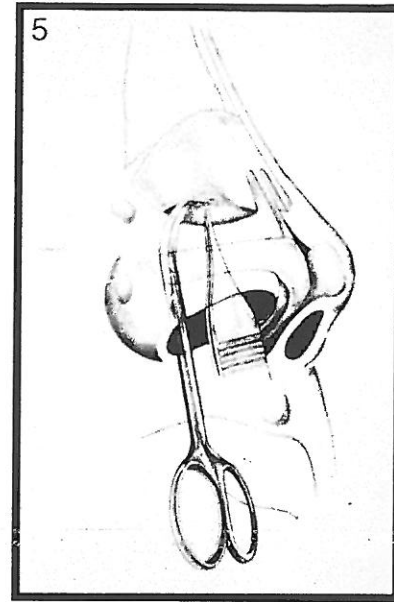


Figure 5. Undermining of mucosa below the upper lateral cartilage in a supraperichondrial plane.

Figure 6. Extent of wide undermining to facilitate advancement without distortion.

Figure 7. Simple closure of flap with 5-0 chromic suture.

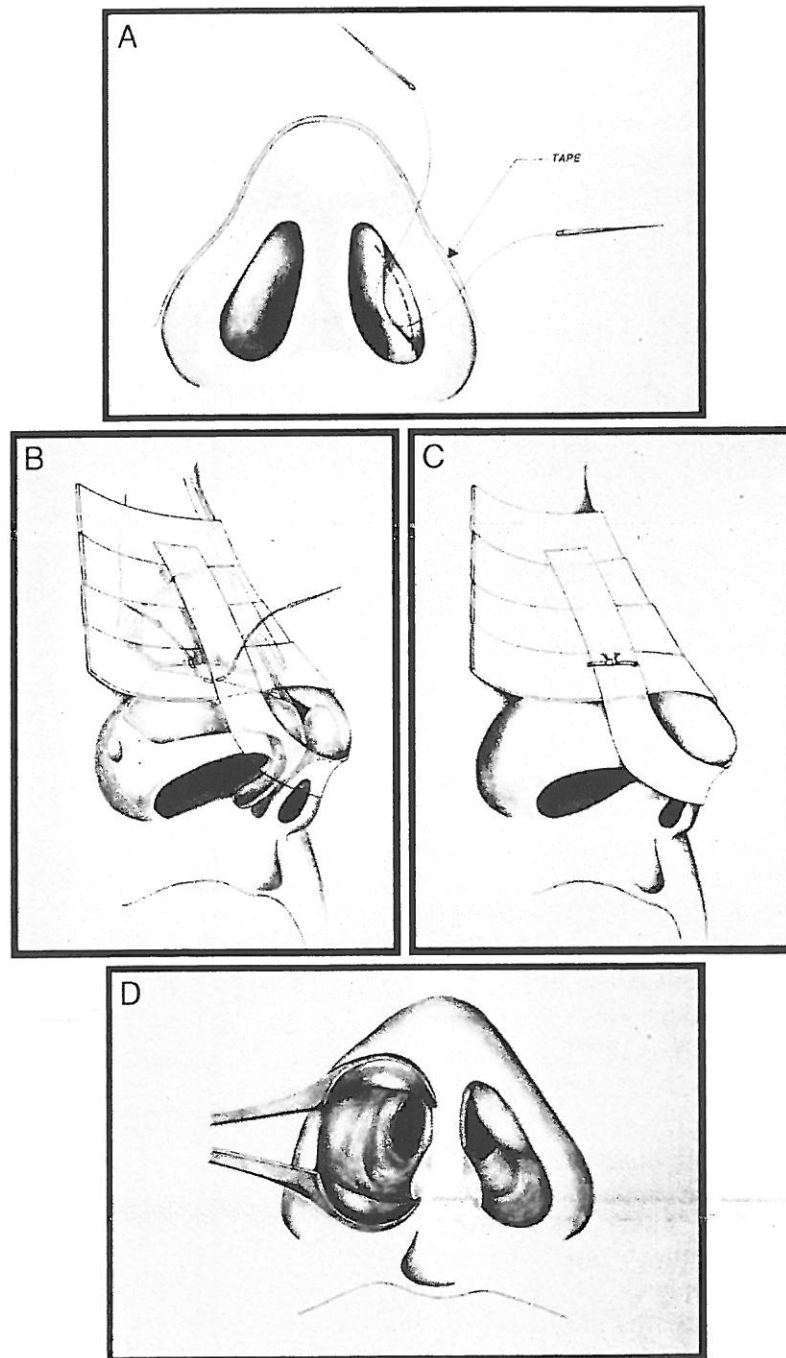


Figure 8A. Pexy suture placement of 4-0 plain gut over flap.

Figure 8B. External view demonstrating nasal taping and pexy suture.

Figure 8C. The pexy suture must not be overly tight. Should be just tight enough to remove dead space, pexing the valve up and open.

Figure 8D. Postoperative day 6 following removal of tape and pexy suture demonstrating patent nasal valve with minimal edema.

Table 1. Post Valvuloplasty Satisfaction

Sex	Age	Side	Other Surgical Procedures	Objective Improvement	Subjective Improvement
M	50	R	Previous rhinoplasty	Improved	Improved
F	61	B	Previous rhinoplasty	Improved	Improved
F	52	B	Previous rhinoplasty	Improved	Improved
M	33	L	Septoplasty	Improved	Improved
F	51	B	Rhinoplasty	Improved	Improved
F	34	L	Previous rhinoplasty	Improved	Improved

collapse either alone or in conjunction with other rhinocological procedures.

References

1. Fischer H, Gubisch W. Nasal valves—importance and surgical procedures [review]. *Facial Plast Surg.* 2006;22:266–280. PMID: 17131269.

2. Lee DS, Glasgold AI. Correction of nasal valve stenosis with lateral suture suspension. *Arch Facial Plast Surg.* 2001;3:237–240. PMID: 11710856.

3. Shah AR, Miller PJ. Structural approach to endonasal rhinoplasty. *Facial Plast Surg.* 2006;22:55–60. PMID: 16732505.

4. O'Halloran LR. The lateral crural J-flap repair of nasal valve collapse. *Otolaryngol Head Neck Surg.* 2003;128:640–649. PMID: 12748556.

5. Bailey et al. *Head and Neck Surgery – Otolaryngology.* 3rd ed. Philadelphia, Pa: Lippencott Williams & Wilkins; 2001.

6. Menger DJ. Lateral crus pull-up: a method for collapse of the external nasal valve. *Arch Facial Plast Surg.* 2006;8:333–337. PMID: 16982991.

7. Hurbis CG. An adjustable, butterfly-design, titanium-expanded polytetrafluoroethylene implant for nasal valve dysfunction: a pilot study. *Arch Facial Plast Surg.* 2006;8:98–104. PMID: 16549736.

2008

Cosmetic Facial Surgery Workshops

FEATURING LIVE SURGERY / RICHMOND VIRGINIA

MINIMALLY INVASIVE COURSE ~ January 26 - June 27

Botox • Fillers • Lip Implants • IPL & Hair Removal • Mole Removal • Chemical Peel
Microdermabrasion • Skin Care • Non Surgical Skin Tightening...and more

COURSE TUITION: \$995 for physicians, \$475 for staff (meals and social events included)

COMPREHENSIVE SURGERY COURSE ~ March 14 & 15 - May 30 & 31 - October 10 & 11

Facelift • Minimally Invasive Facelift • Eyelid Surgery • Browlift • Cheek, Chin & Lip Implants
Face & Neck Liposuction • Radiowave Surgery • Laser resurfacing...and more

COURSE TUITION: \$2,295 for physicians, \$995 for staff (meals and social events included)

Learn the latest cosmetic facial surgery techniques from internationally recognized surgeon, lecturer, and author Dr. Joseph Niamtu, III. Live observational surgeries and lectures, with meals and social activities included. Attendance is limited so make your reservations today. Personal preceptorships available from 1-5 days, call 804.320.2256 for more information.



Joseph Niamtu, III DMD

Fellow of the American Academy of Cosmetic Surgery
Board Certified American Board of Oral & Maxillofacial Surgery
Fellow of American Society of Lasers in Medicine and Surgery

For info go to www.cosmeticsurgeryeducation.com
or call 804-320-2256 • fax 804-320-9626 • Email: niamtu@niamtu.com