


# Take, Give, and Peel: Transconjunctival Blepharoplasty With Adjunctive Fat Grafting and Phenol Peel

The American Journal of  
Cosmetic Surgery  
2016, Vol. 33(4) 184-188  
© The Author(s) 2016  
Reprints and permissions:  
sagepub.com/journalsPermissions.nav  
DOI: 10.1177/0748806816667580  
acs.sagepub.com



Wade D. Brock, MD, FACS<sup>1</sup> and Jim English, MD, FACS, FICS<sup>2</sup>

## Abstract

Surgeons performing lower eyelid blepharoplasties continue to seek an efficient method and predictable outcome to restore the aesthetic ideal of the lower eyelid and cheek junction. Current popular methods frequently fall short. Three patients were chosen as examples from the senior author's past 30 years of practice where they desired improvement in the aesthetic appearance of their lower eyelids. They were treated with a combination of transconjunctival blepharoplasty, fat grafting, and 88% phenol peel. The preoperative and postoperative photos of the patients were analyzed by the patient and senior author. Having undergone the methods described for treatment, all selected patients reported significant improvement with their postoperative appearance. Minimal complications were reported and are mentioned below. No surgical revisions were requested, and the results were stable over an acceptable period of time with an average follow-up time of 2 years. Two of the 3 patients chosen had a follow-up time of at least 8 years. Transconjunctival lower eyelid blepharoplasty when combined with fat grafting and phenol peeling offers a treatment modality to restore the aesthetic ideal of the lower eyelid and cheek junction and, in our hands, is superior to other methods previously described.

## Keywords

blepharoplasty, chemical peels, fat augmentation, fat transfer, fat transplant, fat grafting, phenol peel, transconjunctival blepharoplasty

The real goal of lower eyelid cosmetic surgery should be to establish harmony between the lower eyelid and the cheek. That idea being that there exists a smooth continuum between the lower eyelid and the upper cheek, that the eyelid appears supple rather than deflated or skeletonized, that there are fewer rhytides, and that there is an obvious morphology present which is appreciated more for the fact that it simply exists rather than being obviously noticed. Traditional methods of blepharoplasty alone do not usually address the ideal aesthetics of the eyelid and cheek junction.

A number of approaches have been described in an attempt to improve the appearance of the lower eyelids, and all have their merits.<sup>1-3</sup> In its earliest form, lower eyelid blepharoplasty consisted of an external subciliary approach to the medial, central, and lateral fat compartments to correct the steatoblepharon. Adjuvants to the treatment included tightening the lower eyelid with a canthopexy or canthoplasty, a "pinch" skin excision or skin-muscle flap, laser resurfacing, or TCA peel to name a few of the more popular treatments. In 1989, Henry Baylis et al<sup>4</sup> described the elegant technique of the transconjunctival approach. The transconjunctival approach was reported as early as 1924 in the French literature, Bourque<sup>5</sup>, and was popularized after a more contemporary publication by Tomlinson, *et al*<sup>6</sup> in 1975. This remains our approach of choice. This surgical

procedure to lower eyelid blepharoplasty has gained popularity with the same adjuvants used to address the aging eyelid mentioned above. Although these methods can offer improvement and satisfaction in many cases, they can too frequently fall short of the youthful appearance the patient and surgeon would like. Baylis et al<sup>4(pp1031)</sup> describe that "removal of skin folds and wrinkles in the lower eyelid is difficult to achieve with surgery."

More recently, it has been described and popularized that surgeons should release the oculomalar ligament and then reposition some or all of the fat into the oculomalar groove or nasojugal fold. This has been described with different variations as fat repositioning or septal reset.<sup>7</sup> Some surgeons advocate lifting the midface or suborbicularis oculi fat (SOOF) to improve the lower eyelid and cheek junction.<sup>8</sup> Many find the transposition of fat or SOOF lifting to be rather cumbersome, time-consuming, or unpredictable. We find it unnecessary. We describe a safe, time-efficient,

<sup>1</sup>Arkansas Oculoplastic Surgery, PLLC, Little Rock, AR, USA

<sup>2</sup>English Plastic and Cosmetic Surgery Center, Little Rock, AR, USA

## Corresponding Author:

Wade D. Brock, Arkansas Oculoplastic Surgery, PLLC, 9800 Baptist Health Drive, Suite 500, Little Rock, AR 72205, USA.

Email: eyehawg@yahoo.com

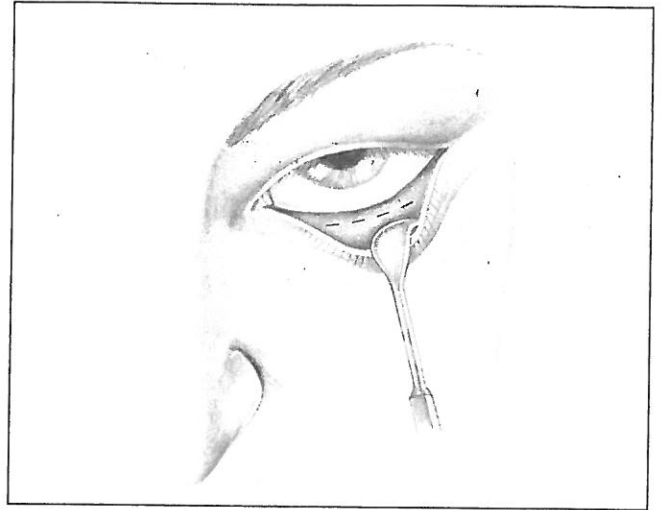
predictable, and satisfying result for the patient and surgeon by combining a transconjunctival blepharoplasty with fat grafting and 88% phenol peel.

## Technique

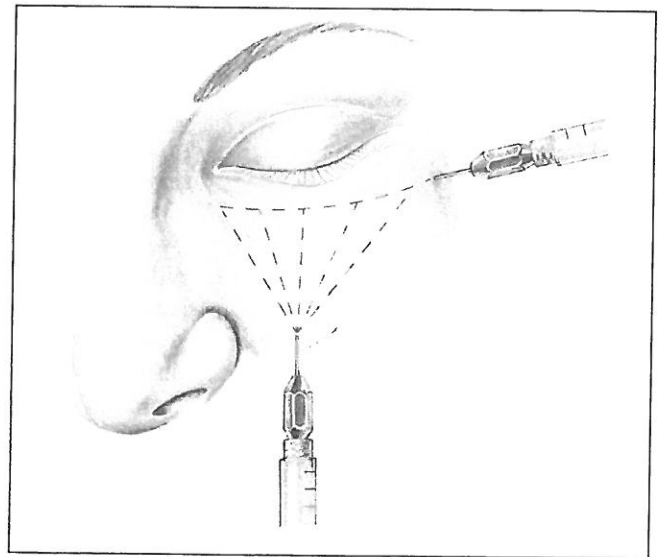
The patient is brought to the operating room and placed under general anesthesia in a supine or lateral decubitus position to harvest fat from the abdomen, outer thigh, or inner knee. We prefer general anesthesia to oral sedation and local for the following reasons: We do not wish for the patient to move. We wish to insure that the patient is as comfortable as possible to decrease episodes of hypertension and bleeding. We do not inject local into the harvesting sites for fat grafting as local anesthesia has been shown to decrease fat cell viability. Also, we find it unnecessary.

The senior author prefers to harvest fat from the abdomen or outer thigh. I tend to harvest fat from the outer thigh or inner thigh immediately above the knee. The fat from the thigh is usually less fibrous and is harvested easier than abdominal fat; that is to say, even though access may be easiest at the abdomen, liposuction tends to yield the fat I need when harvesting from the outer thigh or inner thigh. After prepping the patient with Hibiclens, a 2-mm punch is used to provide entry for the harvesting cannula. If there is a mole, freckle, or other blemish present, this will make an excellent entry point. A Coleman hasp harvesting cannula is introduced. The amount of fat harvested varies from patient to patient, but a good rule of thumb is to harvest a volume of supernatant and infranatant that is about 3 times more than the volume of fat you desire for harvesting. Once the fat is harvested in two 10-cc's syringes, it is centrifuged at 3000 rpm for 3 minutes. The oil is drained from the top of the 10-cc's syringe, and blood is ejected from the tip leaving only the fat. Excess oil may be wicked if desired. The fat is transferred with a coupling Luer-Lock device to 1-cc syringes. A 0.9-mL blunt cannula is applied to the syringe.

While the fat is being processed, attention is turned to the lower eyelids and transconjunctival approach to the orbital space (Figure 1). A Desmarres retractor is introduced to retract the lower eyelids, and a clear lid plate is used to protect the globe. A Colorado tip needle is used to dissect through the inferior conjunctiva between the inferior border of the tarsus and the cul-de-sac, exposing the medial, central, and lateral fat pads posterior to the septum. The fat is expressed or pushed out and not pulled out. Sterile cotton tip applicators are helpful to express the fat gently. The fat that presents easily is removed with cautery while identifying and avoiding the inferior oblique muscle. When a distinct separation between the central and lateral fat pads can be observed externally, we release the interpad septum between the central and the lateral with sharp dissection. Once the desired amount of fat is removed from the medial, central, and lateral fat pads and symmetry is established between the lower eyelids, attention is turned to fat grafting.

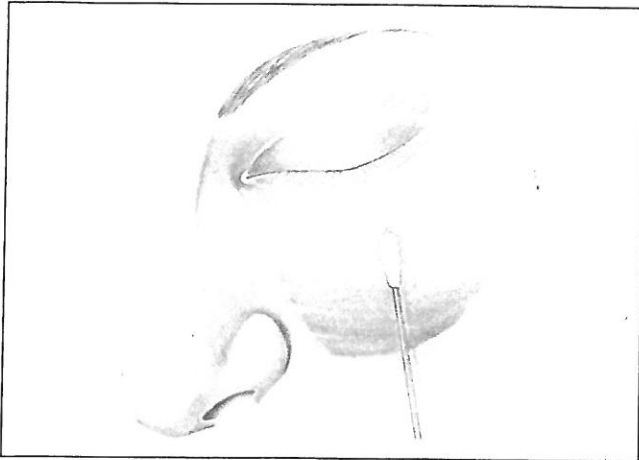


**Figure 1.** The lower eyelid is gently retracted with a Desmarres retractor to expose the palpebral conjunctiva for the transconjunctival incision.



**Figure 2.** A blunt cannula is used to apply fat to the immediately suprapariosteal tissue, superior and inferior to the oculomalar ligament.

A 25-gauge needle is used to make an entry point at the central cheek approximately 2 cm below the eyelid margin. A second entry point is made within the lateral eyelid rhytides or "laugh lines." The 0.9-mL blunt cannula is introduced, and the globe is protected with the contralateral second, third, and fourth fingers. The fat is distributed by careful advancement and withdrawal of the blunt cannula at a depth that is immediately suprapariosteal. The fat is applied on the inferior and superior sides of the oculomalar ligament (Figure 2). Microdroplets are deposited at multiple levels within the suprapariosteal tissue; 1 to 5 cc's of fat may be used to create harmony between the lower eyelid and the



**Figure 3.** A sterile cotton-tipped applicator is used to apply 88% phenol fluidly to the cheek and eyelid, feathering the edges.

cheek with the majority deposited in the upper cheek region depending on the individual.

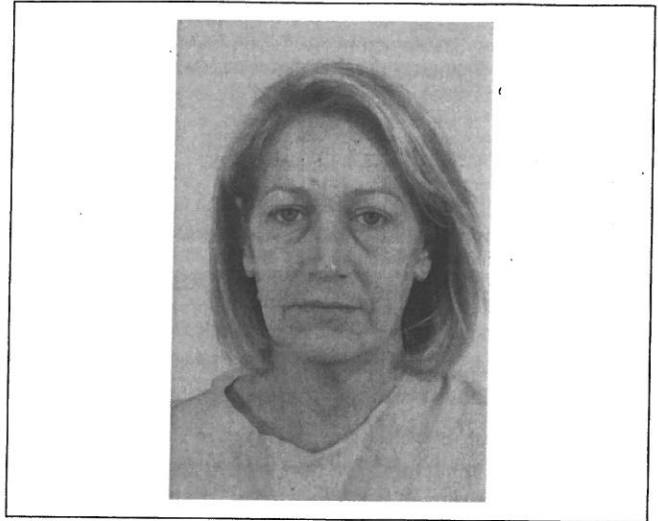Once the fat has been grafted and it is determined that there is a symmetrical improvement of the lower eyelid and cheek, attention is turned to the 88% phenol peel. The patient is not degreased with acetone but alcohol, and cleaned with a moist, sterile 4 × 4 gauze to create a midpapillary-depth peel. This limits absorption of the 88% phenol. A sterile cotton-tipped applicator is saturated with 88% phenol (Figure 3). The cotton-tipped applicator once soaked with the 88% phenol solution is lightly squeezed into a dry 4 × 4 gauze. The wettest stroke is begun on the upper cheek and extended up to the subciliary area. The applicator is applied fluidly to the cheek and lower eyelid skin extending from canthus to canthus feathering it over the eyelid and cheek junction. Mild to moderate frosting should be achieved which indicates the peel has penetrated to the midpapillary dermis. Deep white hoarfrost implies a deeper papillary and/or reticular depth, which would place the patient at higher risk for scarring.

The patient is carefully cleaned with a dry, sterile 4 × 4 gauze. The corneas are examined to be sure they are normal. The patient is awakened and monitored in the postoperative holding area. The patient and family are provided with appropriate postoperative instructions. They return for the first postoperative visit in about 6 days if this is the only procedure performed. A daily phone call is made to discuss the patient's condition, care, and compliance.


## Discussion

Transconjunctival blepharoplasty combined with fat grafting and 88% phenol peel offers a unique and previously undescribed approach to establishing the ideal aesthetic to the lower eyelid and cheek. It is an efficient surgery taking less than approximately 30 minutes to complete in a straightforward case.

Transconjunctival blepharoplasty is a reliable method for fat removal that has proven the test of time over and over.



**Figure 4.** Patient 1-Preoperative photograph.




**Figure 5.** Patient 1-Postoperative photograph.

The advantages it offers include no external scar, less risk of ectropion, less risk of lower eyelid retraction and scleral show, preservation of the orbicularis and other support structures, and no interruption of the septum. One disadvantage is that by itself, it does not address rhytides and/or orbital hollowness.

Fat grafting is also time tested. German surgeon Gustav Neuber<sup>9</sup> is credited with having reported the first fat graft in 1893. Many have described a variety of techniques and uses for fat since then. More recently, fat grafting has been popularized by the work and demonstrations of Sydney R. Coleman.<sup>9</sup> Many of my techniques for fat harvesting and grafting to the periocular area have been adopted from Timothy Marten's discussions at meetings and in publications.<sup>10</sup> Fat grafting is an excellent adjuvant to transconjunctival blepharoplasty. The additional fat serves to reinflate previously deflated areas and




**Figure 6.** Patient 2-Preoperative photograph.



**Figure 8.** Patient 3-Preoperative photograph.



**Figure 7.** Patient 2-Postoperative photograph.



**Figure 9.** Patient 3-Postoperative photograph.

allows “feathering” of the 2 convexities of the lower eyelid and cheek that frequently exist independently in the aging face. Fat grafting can be very effective in a thin or full face. Fat placed in the periorbital area should not be placed in excess because fat in this area tends to last much better than in and around the perioral area.

Phenol peel lost favor following initial enthusiasm from the Baker-Gordon formula popularized in the 1950s.<sup>11</sup> Hetter and Stone have clarified in separate publications that phenol is not the only active ingredient in many of the “phenol” peels.<sup>12-16</sup> Instead, croton oil acts to increase the penetration of phenol. The higher the croton oil concentration, the greater the depth to which phenol will penetrate. Further work by Rullan et al<sup>17</sup> has demonstrated the safety of phenol peeling both with regard to diminished complications and the lack of cardio toxicity when low-concentration croton

oil or no croton oil is used as part of the mixture. No croton oil was used in the peel we described.

As with any surgery, complications are possible. Complications of a retrobulbar hemorrhage with blindness should always be in the forefront of the surgeon’s mind as a possibility. Controlling blood pressure, emesis, anticoagulants, and activities is imperative. Any significant shortening of the skin whether by excision, or in this case, chemical peel, can result in eyelid malposition such as ectropion or retraction. This can be avoided in almost all cases by addressing any significant eyelid laxity with a canthopexy in the mildest of involuntional changes or with a horizontal eyelid tightening when moderate to severe involuntional changes of the lower eyelid are present.<sup>18</sup> Underexcision of eyelid fat is possible. Overinflation is possible. This should not be confused with postoperative edema. Edema tends to be more frequent with fat grafting and can last several weeks. Postoperative



nodularity is possible due to granuloma or "pearl" formation. We find that this can almost always be avoided by keeping your fat graft deposits less than 0.1 cc in any given area. One should be prepared to offer removal in the rare instance that this occurs. We recommend that for most cases, excess fat not be removed prior to 6 months.

Scarring is possible with chemical peeling. Fortunately, we have not experienced this with any significance in our patients. Any surgeon performing phenol peels or deep peels should have deep and broad experience with a number of peels as well as experience in managing burns and/or skin at risk for scarring. It is important to follow the guidelines above to diminish penetration and avoid this complication. If you suspect the patient is on the road to scarring or prolonged erythema, we offer the following protocol:

1. Observe the patient closely that he or she reepithelializes within 7 to 10 days, maintaining moisture throughout and never picking or manually peeling.
2. If reepithelialization is taking more than 10 days, apply a duoderm patch to the raw area every 24 to 48 hours once or twice.
3. Redness persisting more than 4 to 6 weeks can be treated with conservative IPL every 2 to 3 weeks.
4. Very dilute use of Kenalog injections into a hypertrophic elevation of dermal fracturing can be done weekly. No more than 1 droplet to each area each time.

In our cosmetically oriented society, lower eyelid blepharoplasty is frequently requested by patients. Surgeons need a predictable procedure to offer patients who would like to restore a more youthful appearance and harmony between the eyelid and the cheek. Our method of transconjunctival blepharoplasty, fat grafting, and phenol peel accomplishes this goal in an efficient and predictable manner. It is also useful in cases where patients need reoperation following previous surgeries on the lower eyelids.

#### Author's Note

"I" refers to Wade Brock, MD, FACS and the senior author refers to Jim English, MD, FACS, in the article throughout.

#### Declaration of Conflicting Interests

The author(s) declared no potential conflicts of interest with respect to the research, authorship, and/or publication of this article.

#### Funding

The author(s) received no financial support for the research, authorship, and/or publication of this article.

#### References

1. McCollough EG, English JL. Blepharoplasty: avoiding plastic eyelids. *Arch Otolaryngol Head Neck Surg.* 1988;114(6):645-648.
2. Kamer FM, Mikaelian AJ. Preexcision blepharoplasty. *Arch Otolaryngol Head Neck Surg.* 1991;117:995-999.

3. English JL. Discussion: preexcision blepharoplasty. *Arch Otolaryngol Head Neck Surg.* 1991;117:995-999; discussion 1000.
4. Baylis HI, Long JA, Groth MJ. Transconjunctival lower eyelid blepharoplasty: technique and complications. *Ophthalmology.* 1989;96:1027-1032.
5. Bourque. Les hernies graisseuses de l'orbite. Notre traitement chirurgical. *Bull Acad Med (Paris).* 1924;92(3 ser):1270-1272.
6. Tomlinson FB, Hovey LM. Transconjunctival lower lid blepharoplasty for removal of fat. *Plast Reconstr Surg.* 1975;56:314-318.
7. Hamra ST. The role of the septal reset in creating a youthful eyelid-cheek complex in facial rejuvenation. *Plast Reconstr Surg.* 2004;113(7):2124-2141.
8. Hoenig JA, Shorr N, Goldberg RA. The versatile SOOF lift in oculoplastic surgery. *Facial Plast Surg Clin North Am.* 1998;6:205-219.
9. Coleman SR, Mazzola RF. *Fat Injection: From Filling to Regeneration*, Second Edition. St. Louis, MO: Quality Medical Publishing, Inc; 2009.
10. Marten TJ. Combined face lift and facial fat grafting. In: Nahai FR, ed. *The Art of Aesthetic Surgery: Principles and Techniques*. 2nd ed. St. Louis, MO: Quality Medical Publishing, Inc; 2011, pp. 1621-1673.
11. Baker TJ. Chemical face peeling and rhytidectomy: a combined approach for facial rejuvenation. *Plast Reconstr Surg.* 1962;29:199-207.
12. Hetter G. Examination of the phenol-croton oil peel: part I. Dissecting the formula. *Plast Reconstr Surg.* 2001;105:227-239.
13. Hetter G. Examination of the phenol-croton oil peel: part II. The lay peelers and their formulas. *Plast Reconstr Surg.* 2001;105:240-248.
14. Hetter G. Examination of the phenol-croton oil peel: part III. The plastic surgeons' role. *Plast Reconstr Surg.* 2001;105:752-763.
15. Hetter G. Examination of the phenol-croton oil peel: part IV. Face peel results with different concentrations of phenol and croton oil. *Plast Reconstr Surg.* 2001;105:1061-1083.
16. Stone P. Modified phenol peels—role of the application technique. *Clin Plast Surg.* 1998;25:21-44.
17. Rullan PP, Lemon J, Rullan J. The 2-day light phenol chemabrasion for deep wrinkles and acne scars: a presentation of face and neck peels. *Am J Cosmet Surg.* 2004;21:199-210.
18. Anderson RL, Gordy DD. The tarsal strip procedure. *Arch Ophthalmol.* 1979;97(11):2192-2196.

#### Author Biographies

**Wade D. Brock** is managing member of Arkansas Oculoplastic Surgery, PLLC, a private practice in Little Rock, Arkansas, specializing in facial reconstructive and cosmetic surgery. He is a fellow of the American Society of Ophthalmic Plastic and Reconstructive Surgery, Inc. He is a diplomate of the American Board of Ophthalmology and the American Board of Cosmetic Surgery in Facial Cosmetic Surgery.

**Jim English** is a facial plastic and cosmetic surgeon in Little Rock Arkansas. He is a diplomate of the American Board of Otolaryngology, the American Board of Facial Plastic and Reconstructive Surgery and the American Board of Cosmetic Surgery. Dr. English has served as a fellowship director for the American Academy of Cosmetic Surgery for many years.